



ISSN: 2754-8880  
Published 00 11 0000

## How I Do

# It Afferent Loop Obstruction (ALO) With Hyper-Amylasemia And Deranged Liver Function Test, Are We Going To See This Complication More Frequently Again?

M Al-Ardah<sup>1\*</sup>, I Finlay<sup>2</sup>, and D Shetty<sup>1</sup>

<sup>1</sup>General Surgery Department ,Royal Cornwall Hospital , Treliske, Truro TR1 3LJ.

<sup>2</sup>Radiology Department, Royal Cornwall Hospital, Treliske, Truro TR1 3LJ.

\*Correspondence author : Mahmoud Al-Ardah, Consultant Surgeon, 217 picton house Victoria wharf, Watkissway, Cardiff CF11 0SG.

Email: Mahm2000@hotmail.com

## ORIGINAL

### Abstract

Afferent loop syndrome is a known complication of gastric surgery specifically after Billroth II and to a lesser extent a Roux-en-Y reconstruction. However, the incidence decreased over the years proportionally with the decrease in the number of gastric surgery.

Afferent loop syndrome can be either acute or chronic with different presentation and treatment options. The acute type can occur early post operatively or it could be delayed presentation. Acute ALS is associated with complete closed-loop obstruction and is considered a surgical emergency, whereas chronic ALS is mostly related to partial obstruction of the afferent loop.

This rare complication can occur after the single anastomosis gastric bypass (Omega loop bypass) as it is a type of Billroth II reconstruction of gastric pouch-jejunostomy.

With the increase in the number of SAGB performed all over the world as weight reduction surgery for morbidly obese patients surgeons should be aware of this complication and the treatment options.

**Keywords :** Afferent loop obstruction, one anastomosis bypass, complications.

## OPEN ACCESS

*Edited by*  
A. Hussain

*Submitted* 25 Nov. 2023

*Accepted* 24 Dec. 2023

### Citation

M Al-Ardah, I Finlay, D Shetty. How I do it Afferent loop obstruction (ALO) with hyper-amylasemia and deranged liver function test , are we going to see this complication more frequently again?:BJOSS::2025;(5);131-135

## Introduction

Afferent loop obstruction (ALO), is a mechanical complication that infrequently occurs following a gastrojejunostomy. Classically described with a Billroth II gastrojejunostomy, less frequently occurring with other procedures such as a Roux-en-Y gastrojejunostomy, Roux-en-Y oesophago-jejunostomy. Recently with the emergence of OAGB as a common bariatric procedure it should be added to the list of operations that can cause this complication. This bariatric procedure is a form of Billroth II reconstruction with a very long biliopancreatic afferent limb.

Afferent loop obstruction is less frequently seen now as the frequency of distal gastrectomy being performed has decreased. Yet, with the one anastomosis gastric bypass (OAGB) becoming more common as a bariatric procedure, surgeons must be aware of this potential complication. The incidence, however remains small.

Conversion of a OAGB to RYGBP is possible treatment option for many of the complications following OAGB with modification of the technique depending on the reason for conversion.

## Case Presentation

A 49- year- old male patient presented to our Bariatric Unit through the Emergency Department with a twelve-hour history severe and progressive upper abdominal pain, associated with vomiting and poor oral intake.

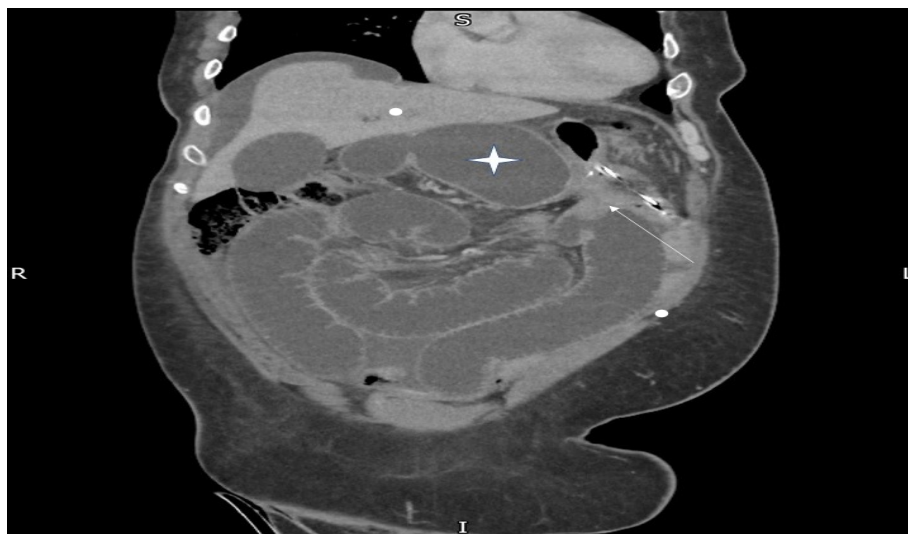
He had OAGB for obesity 2 years previously, performed at another Trust, with endoscopic dilatation of the anastomosis performed twice following the index surgery.

On examination, the patient was tachycardic and mildly jaundiced. Abdominal exam revealed abdominal distention, significant tenderness and guarding in the epigastrium and left upper quadrant. Blood test results are shown in 1. The serum amylase was greater than three normal and initial diagnosis of acute pancreatitis was therefore made. However, owing to his previous surgical history, an urgent portal venous CT scan through the abdomen and pelvis was performed. This showed small bowel obstruction with a transition point at the gastrojejunostomy. This resulted in severe dilatation of the B-P limb and gastric remnant ?? . Urgent laparoscopic converted to open revision of the SAGB to a Roux -en- Y gastric bypass was performed.

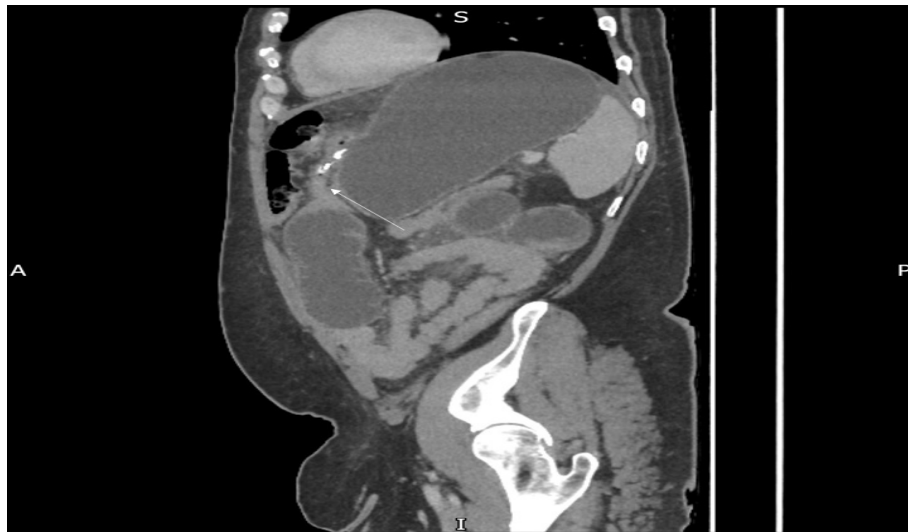Intraoperatively the gastrojejunostomy anastomosis was twisted causing a complete obstruction with the afferent loop severely dilated up to the level of the gastric remnant with impending perforation but no overt ischemia. The patient made an uneventful recovery and was discharged home 10 days post emergency surgery.

**Table 1.** Blood results

Hgb	174 g/L (135-180)
WBC	13.4 (3.7-9.5)
CRP	10 mg/L (0-5)
ALT	104 iu/L (0-55)
Bilirubin	30 umol/L (0-21)
ALP	143 iu/L (30-130)
Amylase	657 iu/L (25-125)



**Figure 1.** Coronal Contrast Enhanced CT In The Portal Venous Phase. Afferent Limb Is Dilated All The Way To The Extruded Stomach (White Star). There Is A Clear Transition Point (White Arrow) Adjacent To The Gastrojejunal Anastomosis.



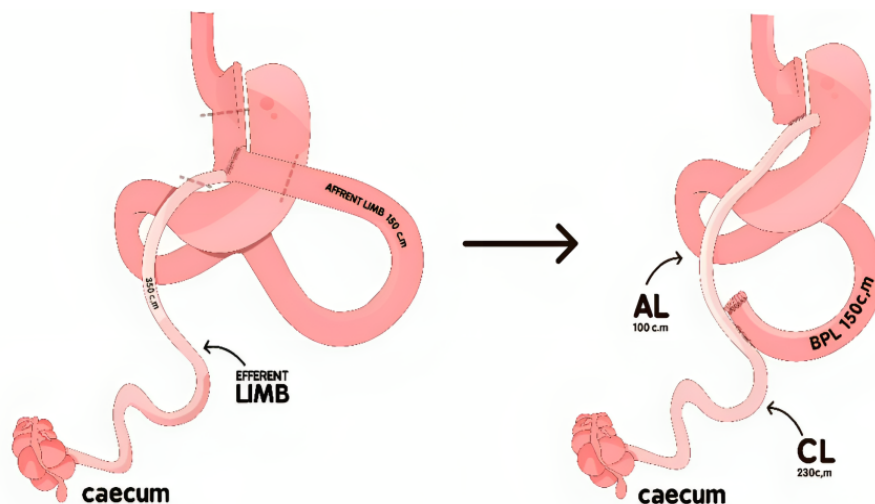
**Figure 2.** Sagittal Contrast Enhanced CT In The Portal Venous Phase Showing The Dilated Afferent Limb With A Transition Point At The Gastrojejunal Anastomosis (White Arrow).

## Surgical Technique

A laparoscopic approach was initially attempted but the bowel was so dilated that safe identification of anatomy was impossible, hence the operation was converted to an open procedure. Conversion to open laparotomy enabled better identification of the anastomosis and post-surgical anatomy.

The entire anastomosis was resected as depicted in Figure 1 using an Endo GIA stapler (Medtronic). Continuity was restored with a Roux-en-Y Gastric bypass reconstruction, performed with an Antecolic Roux limb using the Endo GIA stapler (Medtronic). The mesenteric defect and Petersen's space were closed using a running 2.0 Ethibond (Ethicon) non-absorbable suture. This technique of conversion has been described in the literature (1; 2).

The final measurements showed a biliopancreatic limb of 150 cm, a roux limb of 100 cm, and a common channel of 230 cm. (Graph 1)



**Figure 3.** Illustration Of The Finding And Surgical Technique Used. (AL Alimentary Limb, BPL Biliopancreatic Limb, CL Common Limb).

## Discussion

OAGB is a relatively new operation to treat obesity and its metabolic consequences, a less challenging technique if compared to the classical RYGB. Single anastomosis bypass afforded shorter operative times, less postoperative analgesia use, shorter length of stay, and fewer postoperative complications and has achieved the weight loss goals equalling or outperforming adjustable bands and RYGB (3; 4; 5). The known drawbacks of this procedure include a risk of biliary reflux and anastomotic ulcers or stenosis, and a risk of malnutrition if the common limb is shorter than 2m (6). We present rare complications following OAGB and it should be considered in the differential diagnosis of abdominal pain post OAGB.

Afferent loop syndrome or obstruction was first described in 1950 by Roux, Pedoussaut, and Marchal in post-gastrectomy patients with bilious vomiting (7). ALO can be either acute or chronic, early or late post operatively, and result in complete or partial obstruction.

Chronic ALO following OAGB has been described in the literature (1; 6) however, this is the first reported case of acute ALO post OAGB, to the authors' knowledge. The reason for the obstruction of the afferent limb in OAGB could be due to a stricture, fibrosis secondary to anastomotic ulcer, adhesions, or an internal hernia. Classically the redundancy of an ante-colic afferent loop, with the bowel length longer than 30–40 cm, increases the risk of kinking, volvulus, and entrapment of the limb by adhesions (1). Having a 1.5-2 meter afferent limb, which is often the case in OAGB, is in itself a risk for ALO.

The diagnosis of chronic ALO can be confirmed by measuring bacterial overgrowth, although this requires a jejunal aspirate performed during endoscopy with jejunal intubation. If the microbial load is more than 10<sup>6</sup> organisms per millilitre of aspirate it will be considered pathological (6). Imaging is the cornerstone of diagnosis in ALO with contrast-enhanced CT being the gold standard, especially in the acute setting (8).

A few studies are looking at the aetiology for conversion of OAGB to RYGB, none reported acute ALO as a reason for conversion. Jedamzik et al who looked at 1025 patients with OAGB over an 8year period, found that 8% of the cases were converted to RYGB, they reported the indication for conversion as biliary reflux, a marginal ulcer, malnutrition, weight regain, or anastomotic stenosis (2). This series showed that ALO is not of concern in this operation.

In their series of 16 patients converted from OAGB to RYGB, Landreneau JP reported the primary indications for conversion as intractable nausea and vomiting (n = 8, 50.0%), biliary reflux (n = 3, 18.7%), protein-calorie malnutrition (n = 2, 12.5%), or chronic abdominal pain secondary to marginal ulceration (n = 1, 6.3%) (9).

Blockman and his colleagues however reported chronic ALO in 6/28 of converted cases from OAGB to RYGB which is around 21% of the converted cases. [2] Overall morbidity has been reported at 5.5% (n=55); 35 patients (3.5%) presented with an early complication and 20 patients (2%) presented with a late complication. There were two deaths due to major cardiovascular complications (10).

Different techniques have been described in the literature to convert OAGB to RYGBP, the technique is adjusted according to the indication for conversion and the urgency of the operation. The conversion rate from laparoscopic to open is reported to be up to 25% with this type of operation (9) and this is mainly when this operation is performed in an emergency setting. In our case, it was deemed unsafe to proceed laparoscopically, and early conversion was the best option given the severity of dilatation of the afferent limb and gastric remnant which made the anatomy unclear.

Treatment of acute ALO post-OAGB is surgical and best performed by a bariatric surgeon in bariatric units, the best surgical strategy is to convert to RYGB, and in acute ALO this should be done urgently to prevent catastrophic complications. However, morbidity related to the conversion of OAGB to RYGBP should not be ignored, in 2017 a series published the morbidities post-conversion as high as 41%, 7/17 of the patients developed major post-operative events.

Interestingly, three patients required a re-do operation for entero-enteric staple line bleeding (11). In conclusion, Acute ALO is a rare complication of OAGB for obesity and it should be considered as part of the working diagnosis in patients presenting with obstructive symptoms. Prompt diagnosis and immediate surgical intervention is crucial.

## Conflict Of Interest

All authors declare no conflict of interest of any kind.

## References

- [1] Bolckmans R, Arman G, Himpens J. Efficiency and risks of laparoscopic conversion of omega anastomosis gastric bypass to Roux-en-Y gastric bypass. *Surgical Endoscopy*. 2019;33:2572-82.
- [2] Jedamzik J, Bichler C, Felsenreich DM, Gensthaler L, Eichelter J, Nixdorf L, et al. Conversion from one-anastomosis gastric bypass to Roux-en-Y gastric bypass: when and why—a single-center experience of all consecutive OAGB procedures. *Surgery for Obesity and Related Diseases*. 2022;18(2):225-32.
- [3] Kansou G, Lechaux D, Delarue J, Badic B, Le Gall M, Guillerm S, et al. Laparoscopic sleeve gastrectomy versus laparoscopic mini gastric bypass: one year outcomes. *International Journal Of Surgery*. 2016;33:18-22.
- [4] Kular K, Manchanda N, Rutledge R. Analysis of the five-year outcomes of sleeve gastrectomy and mini gastric bypass: a report from the Indian sub-continent. *Obesity surgery*. 2014;24:1724-8.
- [5] Lee WJ, Ser KH, Lee YC, Tsou JJ, Chen SC, Chen JC. Laparoscopic Roux-en-Y vs. mini-gastric bypass for the treatment of morbid obesity: a 10-year experience. *Obesity surgery*. 2012;22:1827-34.
- [6] Kassir R, Blanc P, Lointier P, Breton C, Debs T, Tiffet O. Laparoscopic revision of an omega loop gastric bypass to treat afferent loop syndrome. *Obesity surgery*. 2015;25:1976-8.
- [7] Roux G, Pedoussaut R, Marchal G. Afferent loop syndrome of gastrectomized subjects. *Lyon chirurgical*. 1950;45(7):773-80.
- [8] Ramos-Andrade D, Andrade L, Ruivo C, Portilha MA, Caseiro-Alves F, Curvo-Semedo L. Imaging the postoperative patient: long-term complications of gastrointestinal surgery. *Insights into Imaging*. 2016;7(1):7-20.
- [9] Landreneau JP, Barajas-Gamboa JS, Strong AT, Corcelles R, Kroh MD. Conversion of one-anastomosis gastric bypass to Roux-en-Y gastric bypass: short-term results from a tertiary referral center. *Surgery for Obesity and Related Diseases*. 2019;15(11):1896-902.
- [10] Chevallier JM, Arman GA, Guenzi M, Rau C, Bruzzi M, Beaupel N, et al. One thousand single anastomosis (omega loop) gastric bypasses to treat morbid obesity in a 7-year period: outcomes show few complications and good efficacy. *Obesity surgery*. 2015;25:951-8.
- [11] Poghosyan T, Caille C, Moszkowicz D, Hanachi M, Carette C, Bouillot JL. Roux-en-Y gastric bypass for the treatment of severe complications after omega-loop gastric bypass. *Surgery for Obesity and Related Diseases*. 2017;13(6):988-94.